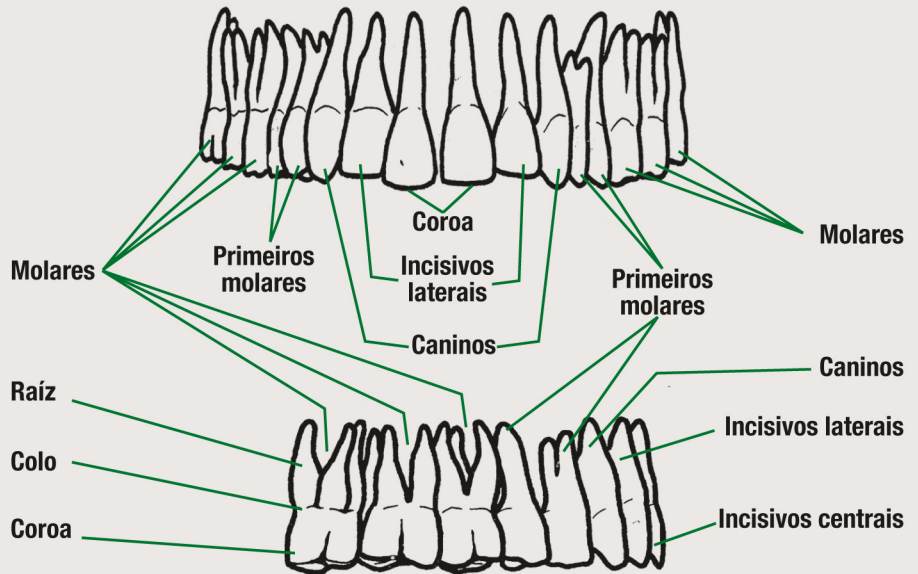
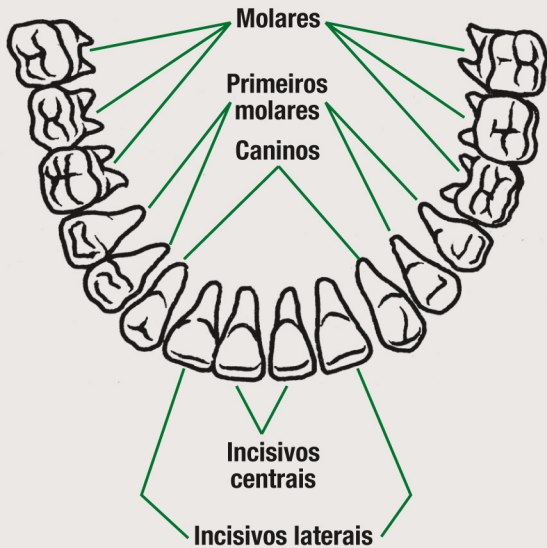
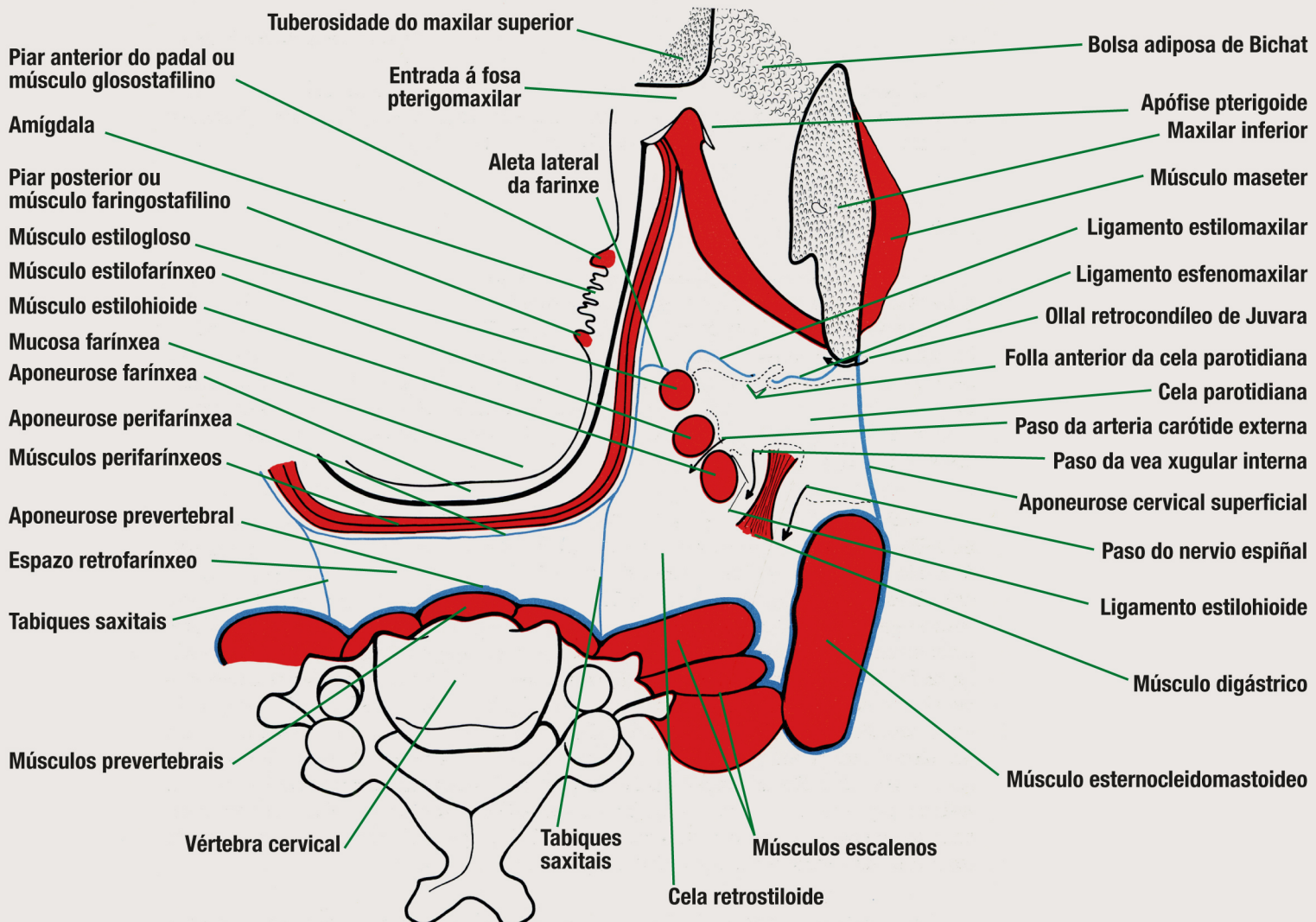


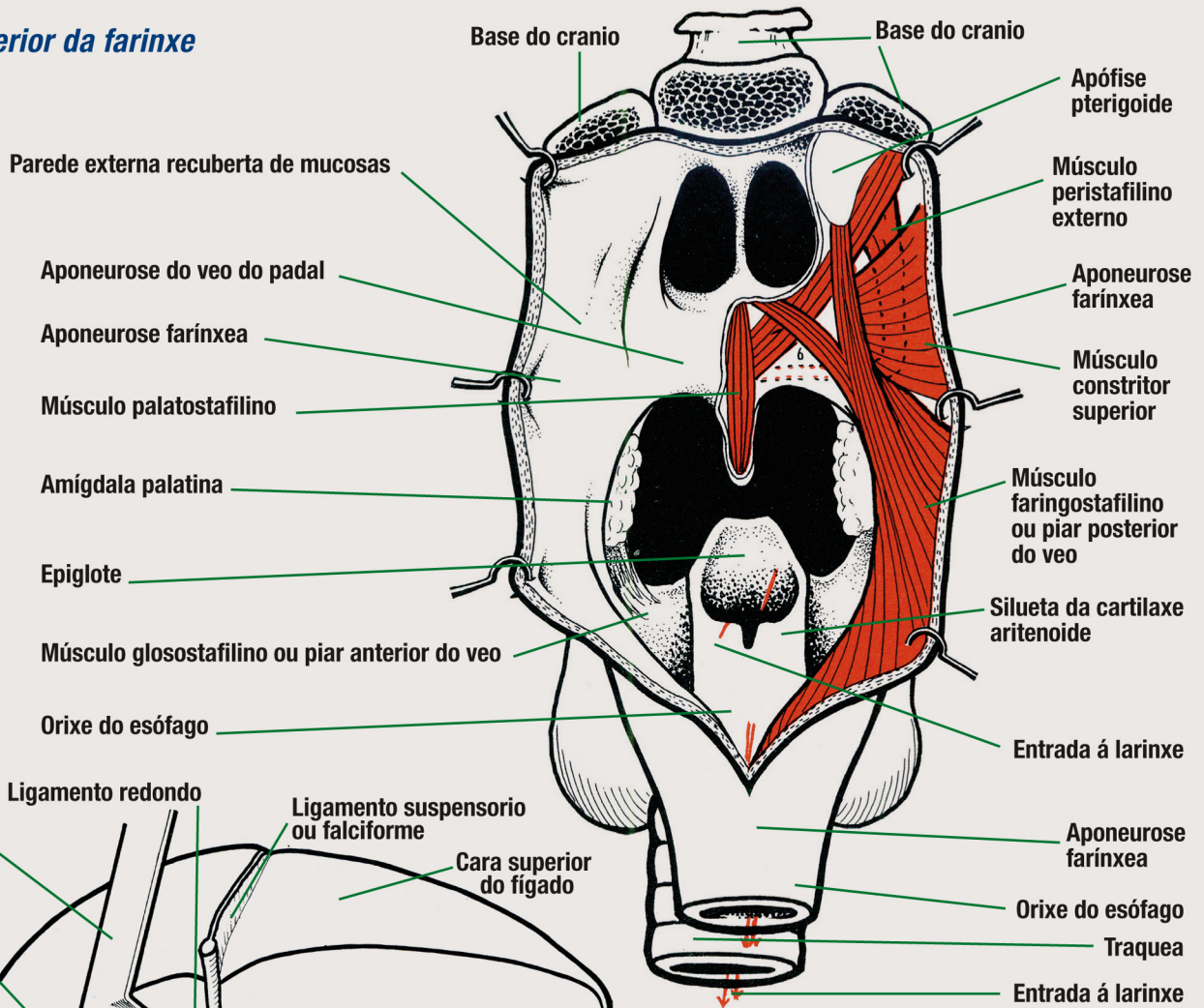
Diferentes vistas da dentición



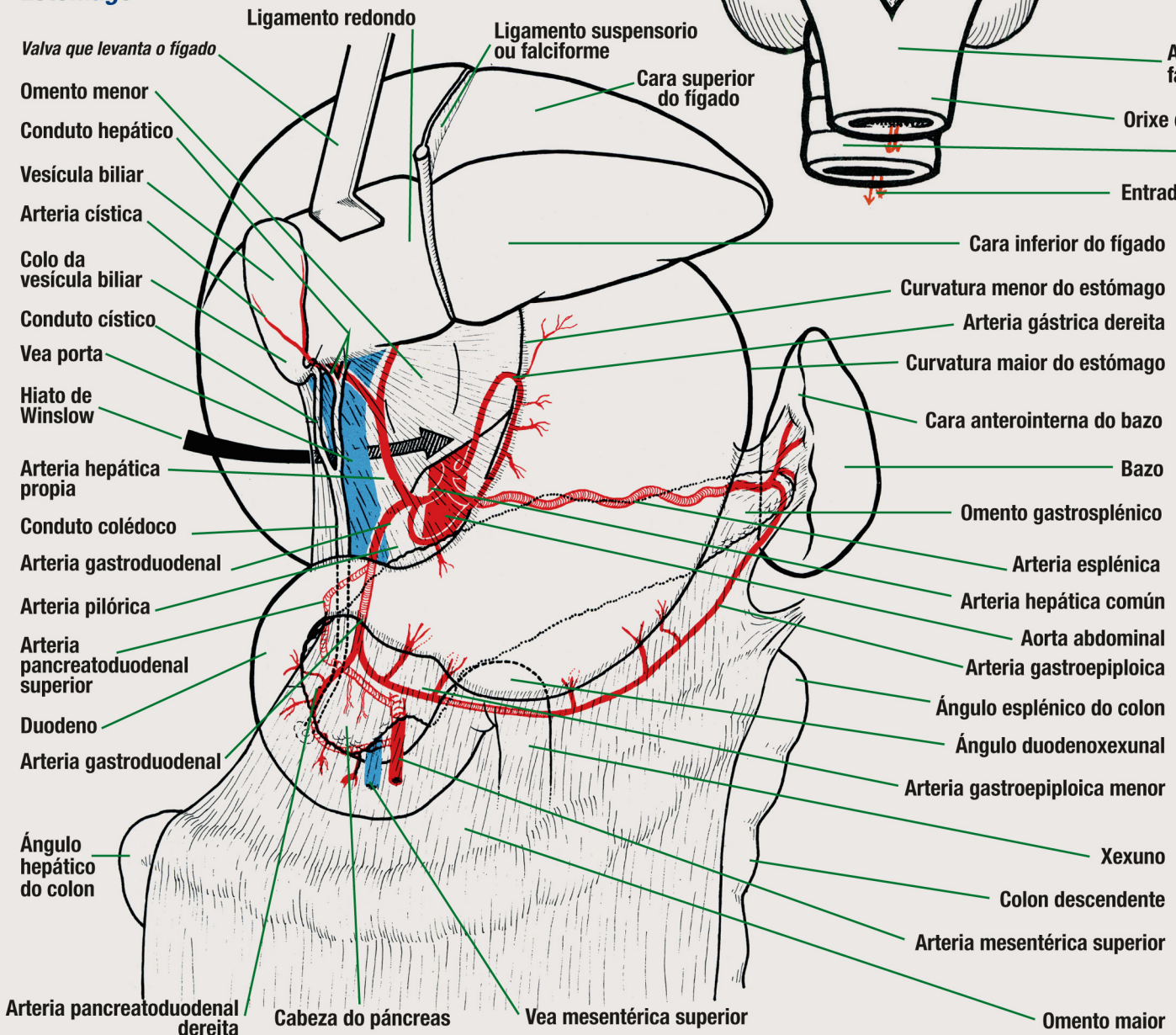
Tabiques e celas do espazo perifarínxeo



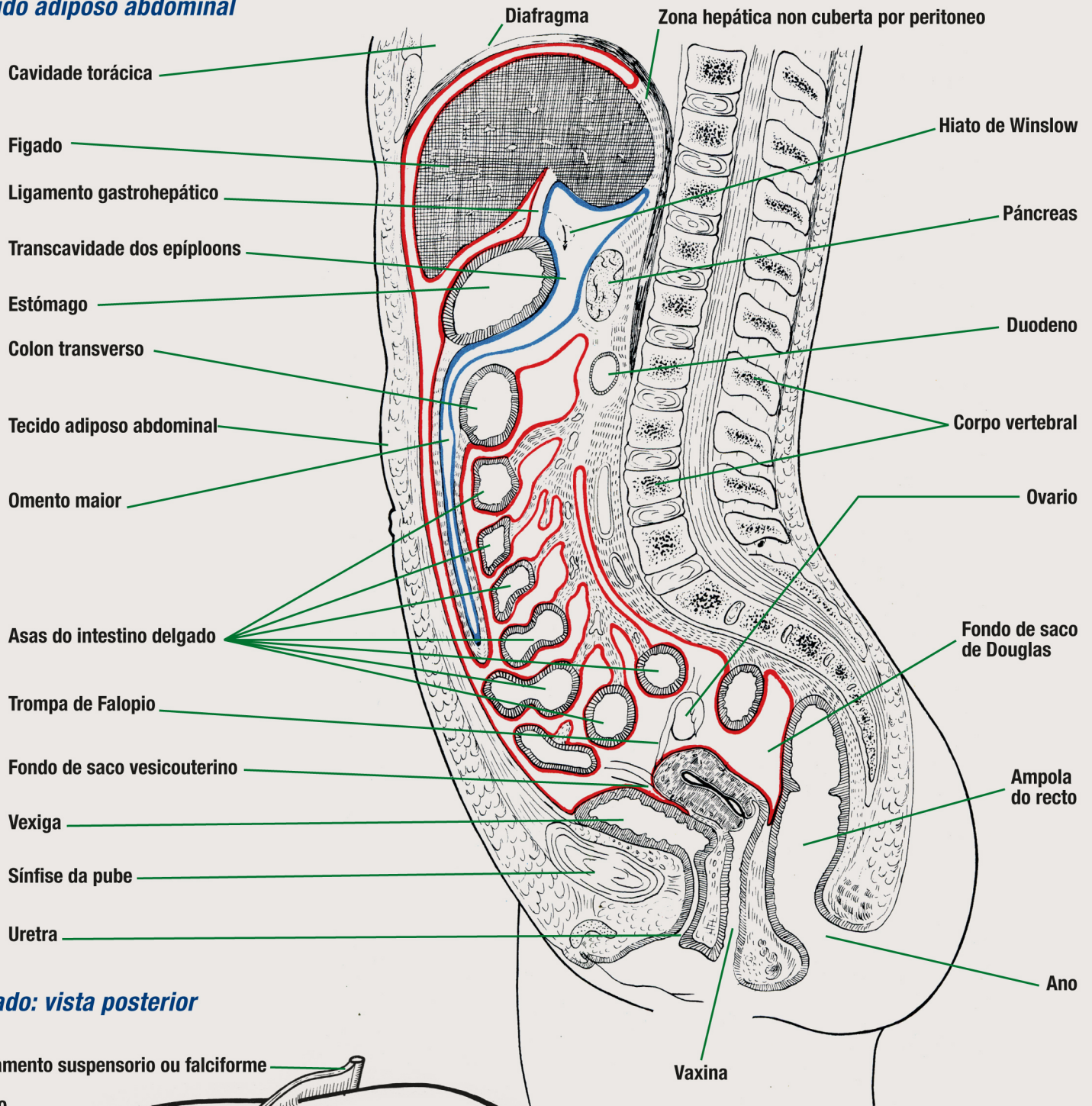
Cara posterior da farinxe



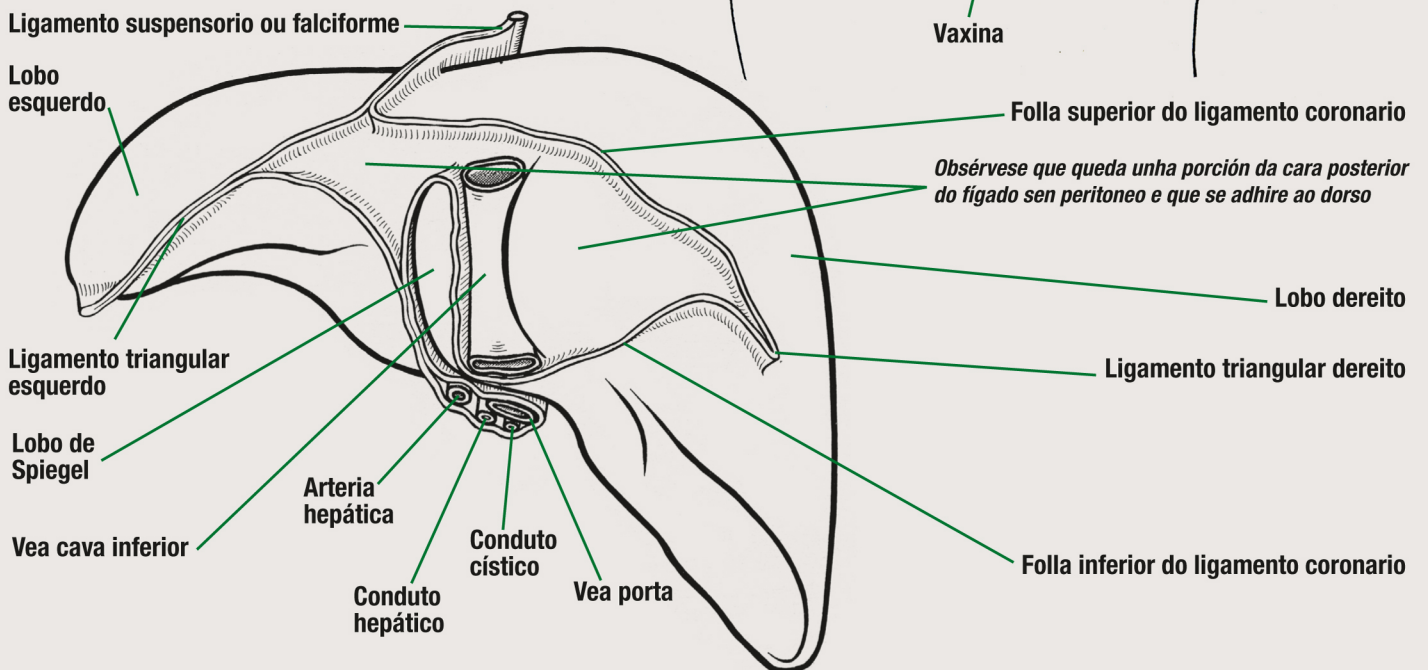
Estômago



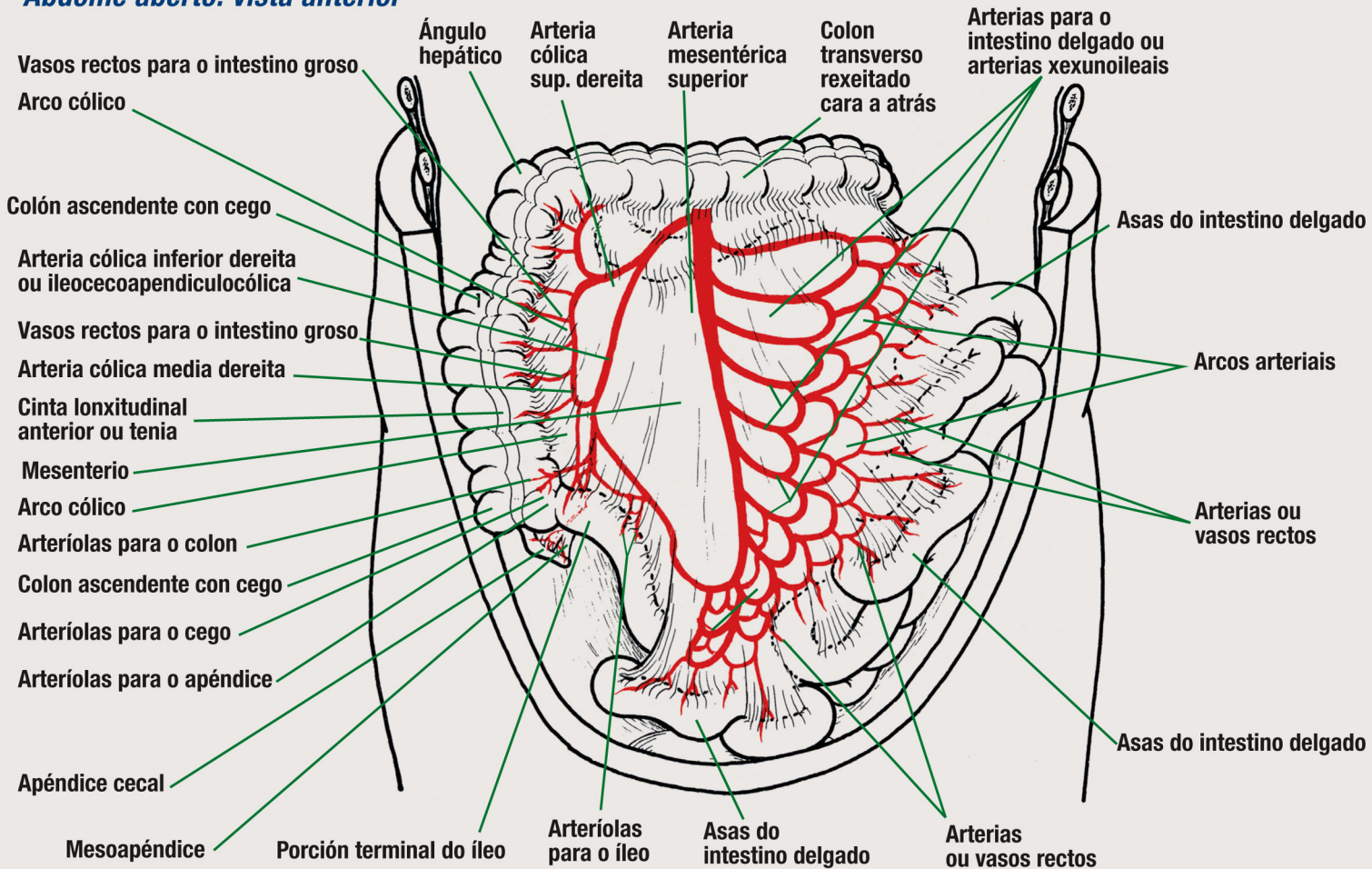
Tecido adiposo abdominal



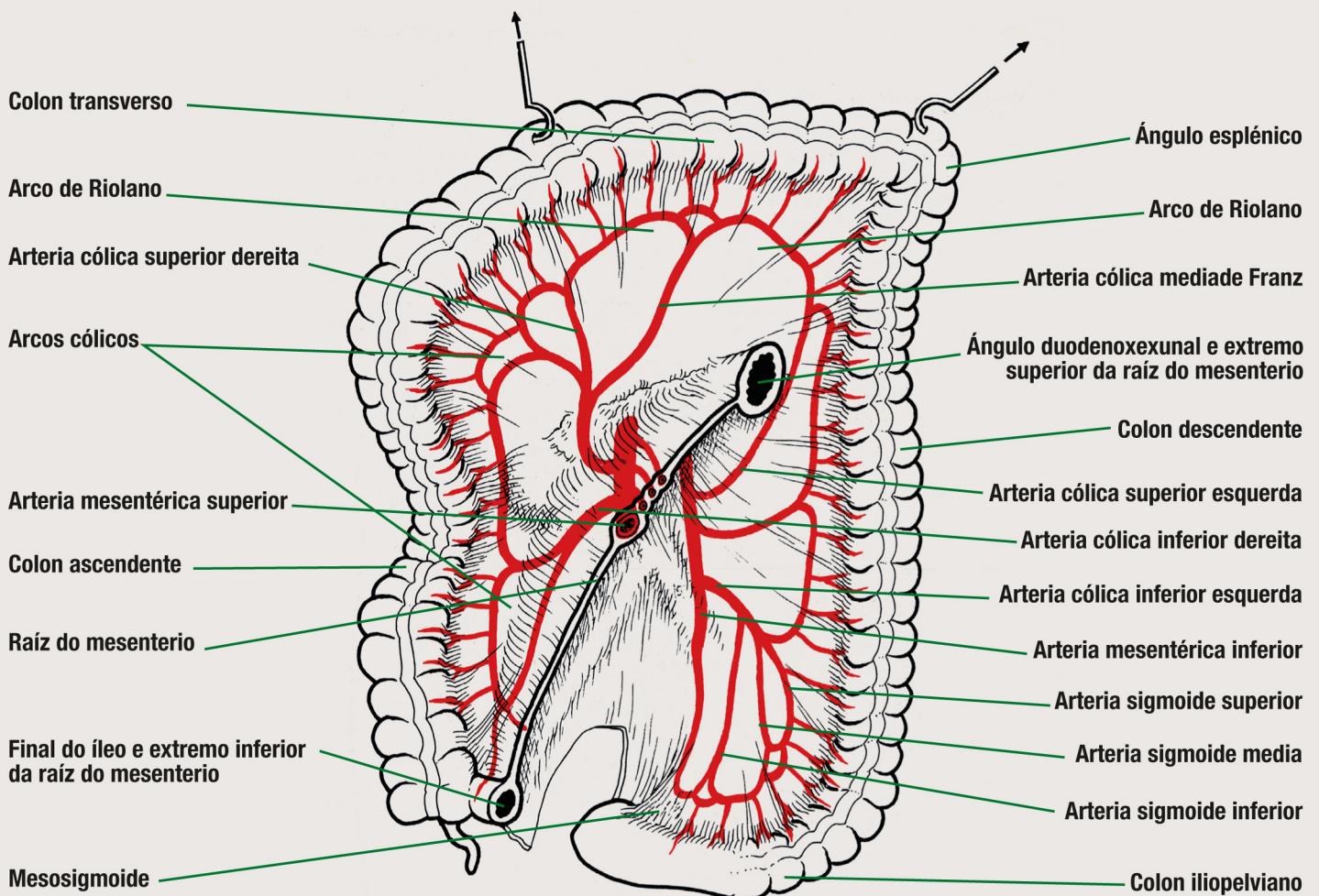
Fígado: vista posterior



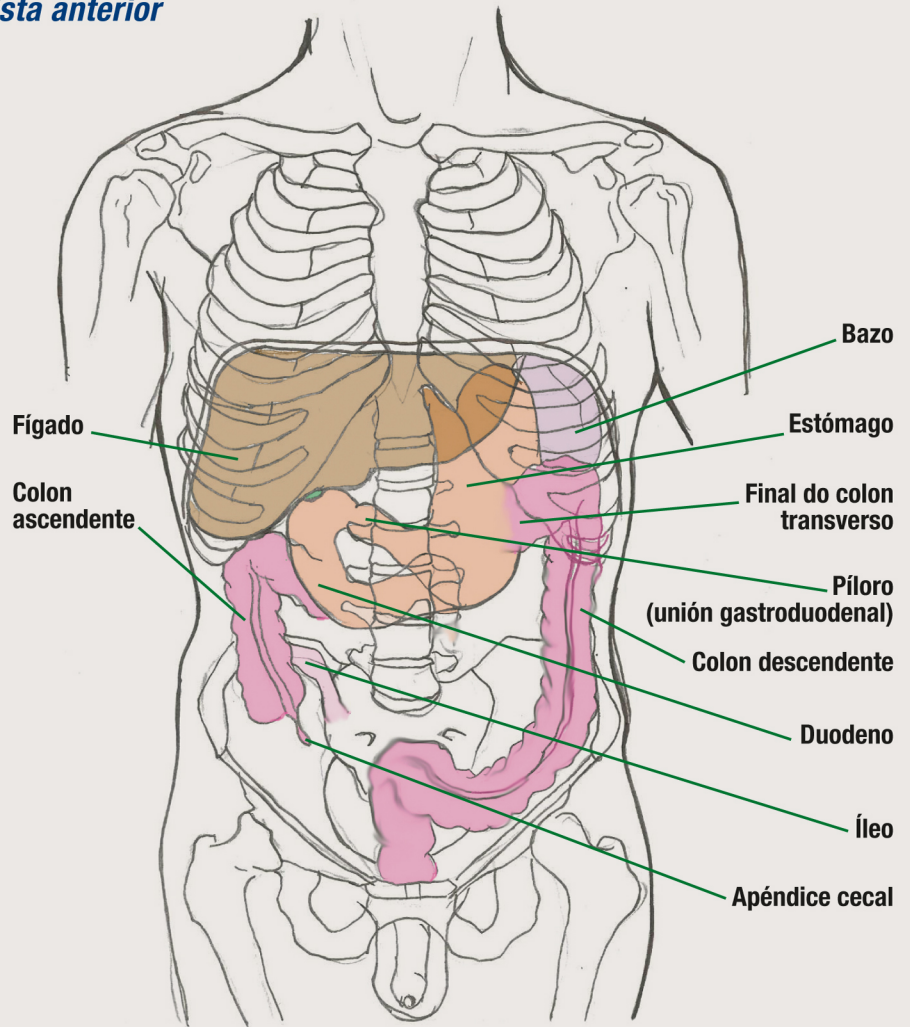
Abdome aberto: vista anterior



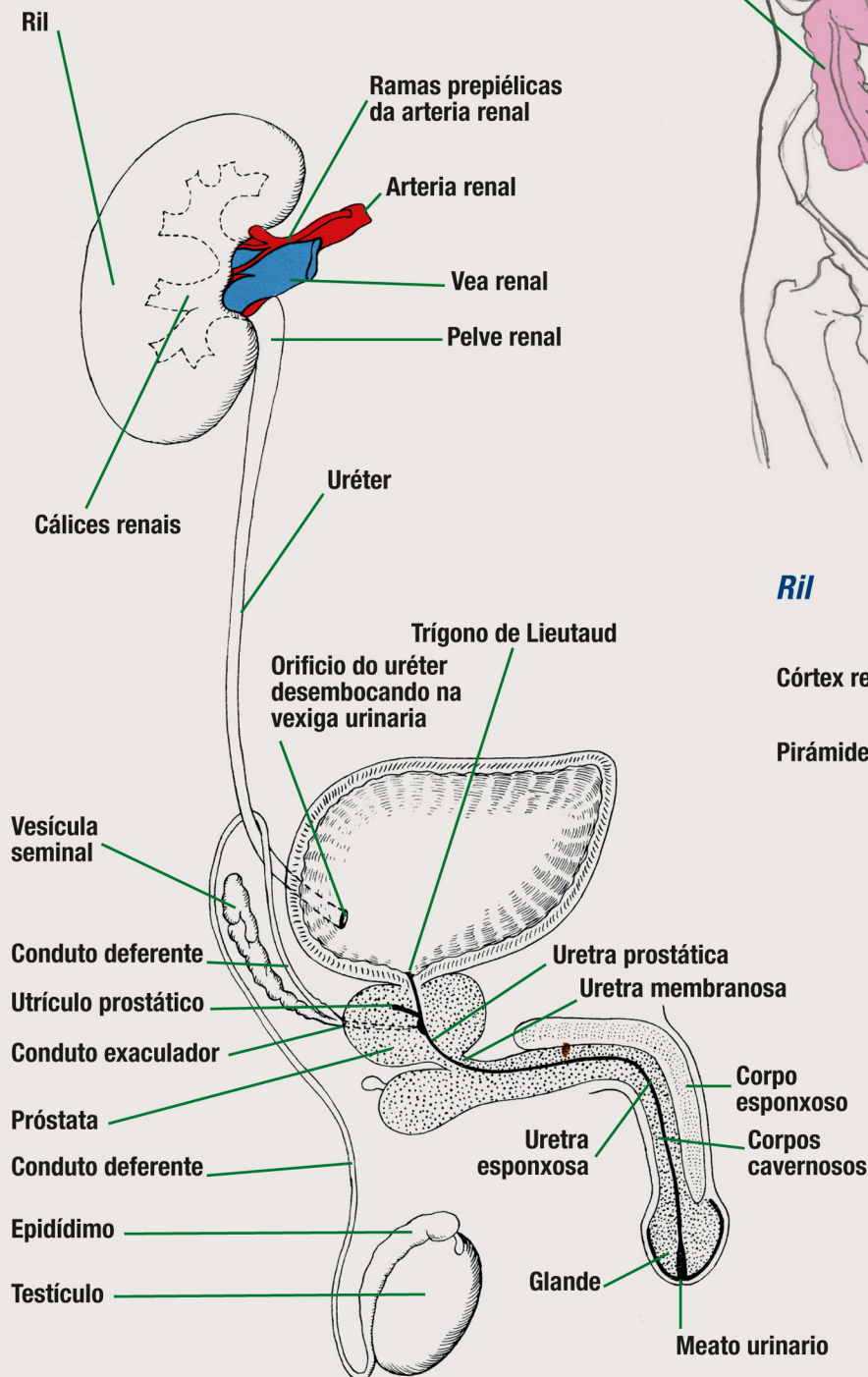
Colon transverso levantado por uns ganchos: vista anterior



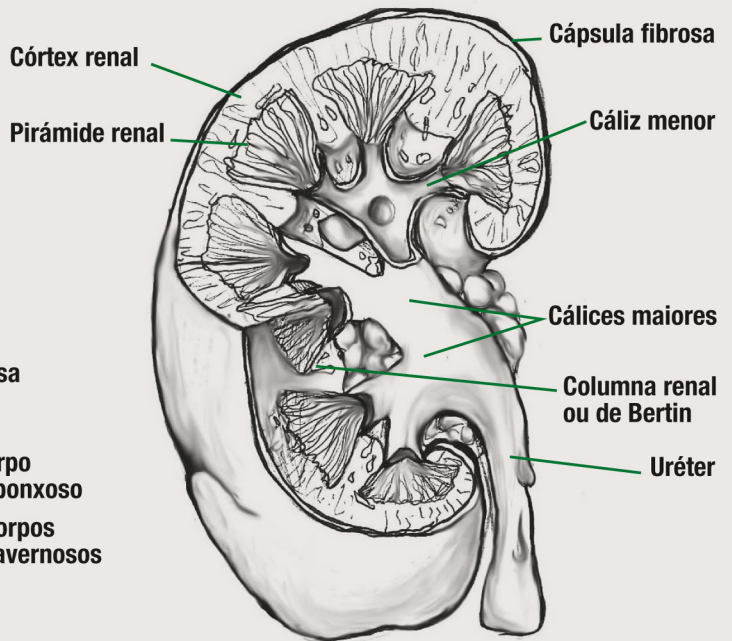
Tronco e abdome com alguns órgãos transparentados: vista anterior



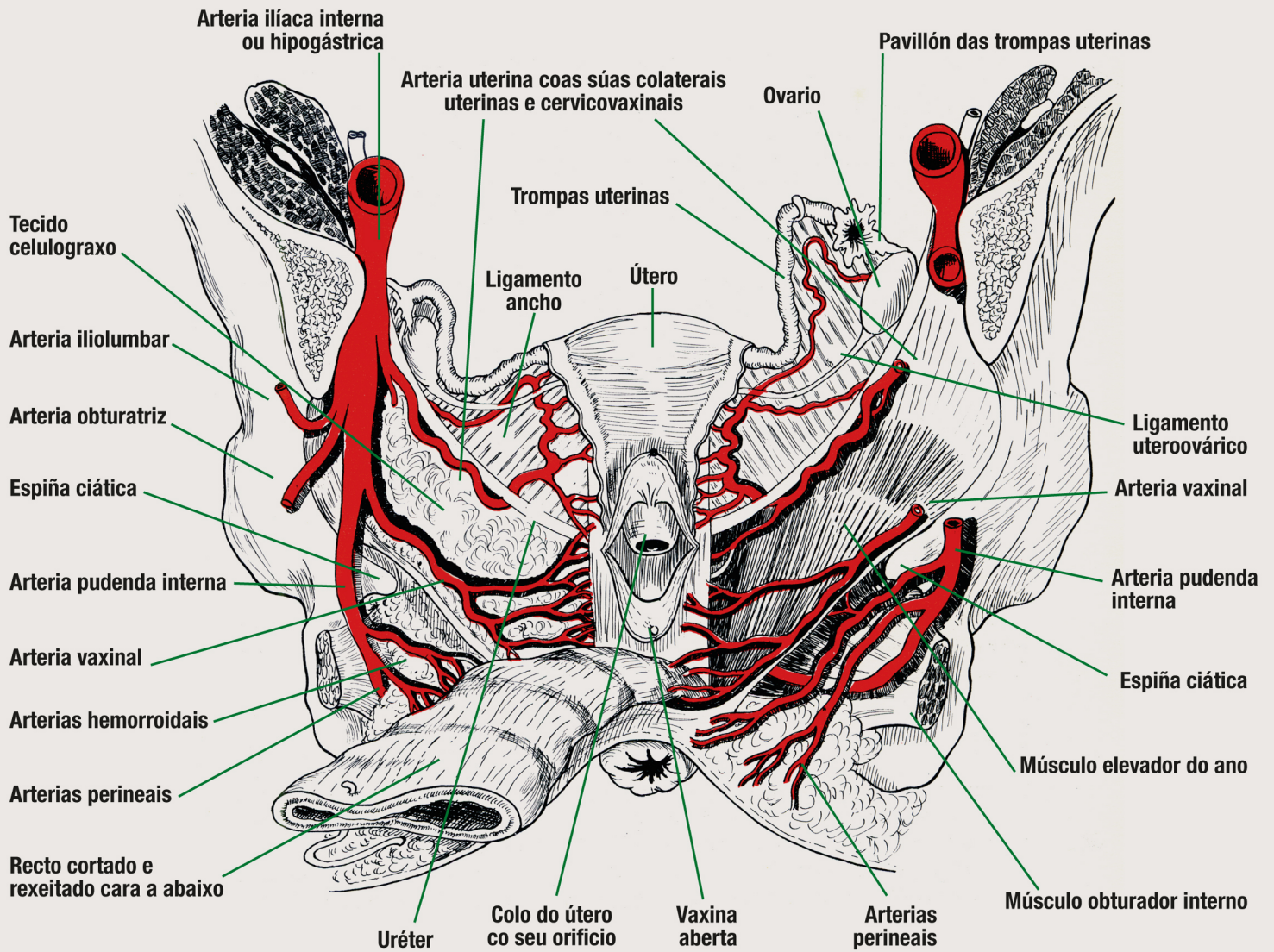
Sistema uroxenital masculino



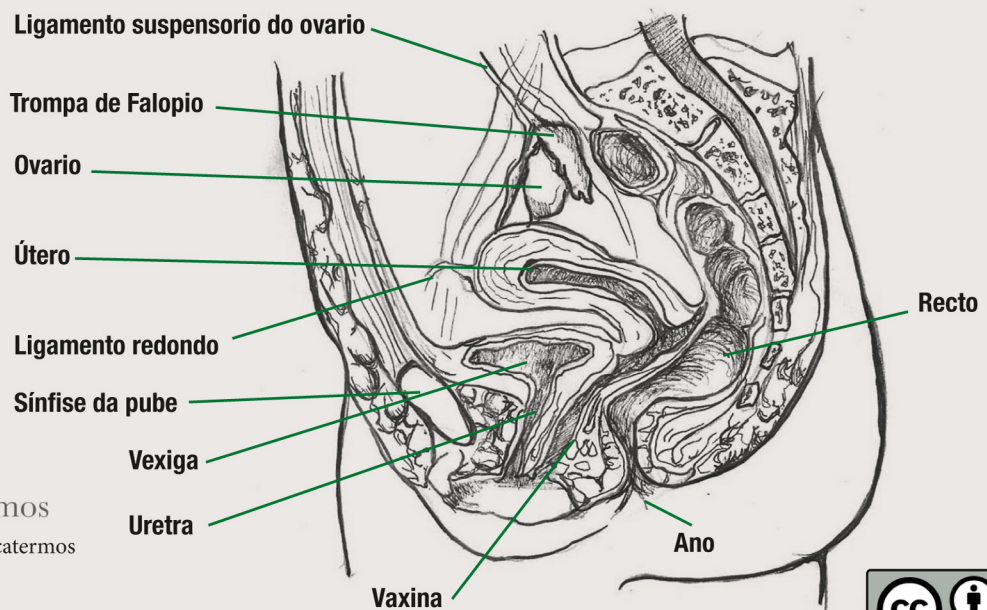
Rim



Útero e anexos: vista posterior



Corte saxital do sistema xenital feminino



Consulta aquí os equivalentes noutros idiomas destes termos



bUSCatermos
www.usc.gal/buscatermos